

# Effect of Pregnyl (HCG) on Histological Structure of Testes in Albino Mice

Salam Maseer Juma'a , Thekra Atta Ibrahim

Department of Biology, College of pure Science of Education, University of Diyala, Diyala, Iraq

## Article Info

### Article history:

Received: 20, 05, 2024

Revised: 21, 08, 2024

Accepted: 05, 09, 2024

Published: 30, 09, 2024

### Keywords:

Testis

Sertolic cells

Pregnyl

Seminiferous tubules

Leydig cells

## ABSTRACT

Pregnyl is a placental hormone, produced mainly during the entire period of pregnancy, making it the vital sign for detecting pregnancy. The current study shed light on effect of Pregnyl on histological structure of testes in Albino mice. The study included 15 mice, and animals are divided into two groups. First group included five mice and second group included ten mice. They were placed in separate cages with continuous monitoring and cleaning throughout the study. First group was injected with Pregnyl at a concentration of 0.1 mg./kg and the second group at a concentration of 0.2 mg/kg for a period of 30 days. After the end of the experiment, the animals were sacrificed, dissected, and their testicles were removed for the purpose of histological study. The outcome of this study shows that the animals in the two empirical groups which treated by Pregnyl showed changes in thickness of seminiferous tubules of testis wall and their shrinkage, as their manifestation becomes wavy and offbeat. furthermore, atrophy was noted in a few of seminiferous tubules, and the sloughing and exhaustion of some germ cells and their accumulating in lumen of seminiferous tubules. Additionally, degeneration was observed in some Sertolic cells.

This is an open access article under the [CC BY-SA](https://creativecommons.org/licenses/by-sa/4.0/) license.



## Corresponding Author:

Salam Maseer Juma'a

Department of Biology, College of pure Science of Education

Diyala University

Baqubah City, Diyala Governorate, Iraq

Email: [salammsser92@gmail.com](mailto:salammsser92@gmail.com)



## 1. INTRODUCTION:

Pregnyl is a diverse hormone of glycoprotein made with chorionic trophoblast, non-nutrient blast and tumor trophoblast and in comparison, low condensation by "pituitary gland" [1]. Many attempts for determining its function in the pregnancy enlarged dramatically when the first test of urine was developed in 1927, identifying the existence of a gonad stimulant, that was later verified as Pregnyl in urine samples [2]. There have been a lot of studies about three-dimensional composition of since 1975, N- and O-bound manner of glycosylation, and the identification of its isotopes in several gestational trophoblastoma illnesses after several researches focusing on uses in medicine of glycosylated forms of Pregnyl testing [3],[4]. In addition, biosynthesis studies, receptor activity and biologicals processes by [5], [6] and gene expression by [7], and many others. However, variability and enormous possible of this glycoprotein have not quite yet been completely comprehended [8]. Pregnyl also includes follicle-stimulating hormone (FSH), luteinizing hormone (LH) and thyroid-stimulating hormone (TSH), a non-gonadometer-directed organ. Pregnyl and (LH) are closely associated to origins of evolution. Through same hormone collection, different types display a wide range of comparable and unique structural and biological traits. As an example,  $\alpha$  subgroup of (GPHs) is encrypting with same gene stated in the pituitary gonadotropins, thyrotrophen cells, and chorionic trancytial trophoblasts in all vertebrates. Thus, all GPHs are comprised of two subunits, alpha ( $\alpha$ ) and beta ( $\beta$ ) are non-covalently linked, and each subgroup has a cysteine in the middle node model, that defines its three-dimensional structure [9]. Also, alpha ( $\alpha$ ) subgroups of (FSH), (TSH), (LH), and HCG correspond to N-bound glycosyl binding sites and distinct subgroups to a fluctuating figure of N-bound and O-bound glycosylation sites that give a biological distinction to every hormone [10]. Furthermore, the  $\beta$  subunit shows a  $\geq 85\%$  symmetry between Pregnyl and (LH) [11] and [12],

so the difference between the two hormones is only due to the presence of (24) amino acids in carboxylic conclusion of (HCG $\beta$ ). Pregnyl contains 24 additional amino acid extensions, referred to as C-terminal expansion or carboxylic terminus peptides which contains more possible glycosylated sites and a greater diversity of structures [13] and [14]. It is essential to note that GPH's chemical makeup plays a role in the cardiovascular system's ability to maintain it, that is, glucocortic (GPHs) with (CTP) exhibit a longer half-life of 1.5-2.5 days and without a very short period of 5-30 minutes. They are then disposed from blood with capturing the lever, renal either urine or glomerular filtration [15]. These results are highly essential for timeliness and precision of external Pregnyl measures (Test of Pregnancy) [16].

## 2. MATERIALS AND METHODS

The specific dose of pregnyl (HCG) was prepared based on the lethal half-dose (LD<sub>50</sub>) valued in mice (0.012 mg pregnyl (HCG)/kg body weight) [17]. The concentration (0.2 mg / kg) of the drug was also selected to evaluation its effect on the histological structure of the testicles, whereas mice included in the studies had weights ranging from 20 to 30 g, and the mice were injected with the required amount of the drug according to the specified concentration by intramuscular injection once. One per day for (30 days). The quantity of the drug administered to the study's animals was computed using the formula below:

$$\frac{X}{D} = \frac{W_{mice}}{1000}$$

Whereas:

*X*: The quantity of the drug to be injected to experiment animals.

*D*: Specific dose of drug (0.2 mg/kg body weight).

*W<sub>mice</sub>* The weight of the mice utilized in experiment, which ranges between (20-30) g.

## 3. ANIMALS USED IN HISTOLOGICAL EXPERIMENTS AND STUDY:

Fifteen male mice, all white, from animal house were utilized in this research, in Department of Biology - College of Education for Pure Sciences - University of Diyala, and their median weights ranging from 20 to 30 g and they ranged in age from eight to ten weeks. Two groups of these animals were chosen at random and the specifics of each group went as followed:

The study included 15 mice, and the animals are divided into two groups. The first group (control group) included five mice and the second group (experimental group) included ten mice. They were placed in separate cages with continuous monitoring and cleaning throughout the study period. The first group was injected with Pregnyl at a concentration of 0.1 mg. /kg and the second group at a concentration of 0.2 mg/kg for a period of 30 days, as well as animals were given Chloroform anesthesia at final stage of investigation, and after that, mice's testis were dissected, treated by Formalin for whole day, and then cleaned via tap water before being preserved in 70% Alcohol. The textile was produced using the procedure described in [18], where prototypes of the tissue passed an ascending chain of Ethyl, subsequently applied along with Xylene for warming, subsequently covered in the Paraffin wax and wax molds were carved with a rotating a microtome to a seven-micron thickness. The acquired glass profiles were colored utilizing dye Haematoxylin\_and\_Eosin stain (H&E) corresponding to method utilized in [19] (Yano and Dolder). The glass sections were stained with Canada balsam, and using a light microscope that had a digital camera attached, the samples were inspected and photographed. The spectrometers were calibrated in the laboratory as mentioned in [20]

## 4. RESULTS AND DISCUSSION:

Testicle is most important organ of the male reproductive system. It has two main functions, the first being the production of the steroid hormone and spermatozoa [21]. There are many different factors that affect spermatogenesis, among these elements are chemical agents like stimulant drugs, pesticides and toxic chemical elements that pollute environmnt [22]. The current study's findings demonstrated that mice given an injection of (0.2 mg of HCG / kg body weight) showed clear histological abnormalities atrophy in some seminal tuules and an obvious in thickness and constriction of seminiferous tubule walls, giving tubules a curving, uneven look overall, along with asymmetric seminal the epithelium as shows in the figure (1). That agree with that finding in [23] According to statement, the impacted basement surface is crucial for preserving the movement of materials within the spermatogenic germ epithelium and interstitial tissues, as well as the form, construction, and functionality of all of these cells. Whereas [24] he pointed out that increasing the link among Semin tubules and tissue that surrounds them is weakened by their thickness, and several clinical diseases, particularly those affecting the function of Sertolic cells, arise inside the testis as wall thickness increases, as they affect cell differentiation. Microbial and inhibition of spermatogenesis. [25] Sertolic cells release collagen strands (IV), which thicken the walls of seminiferous tubules, leading to poor spermatogenesis.

The results of the macroscopic examination of the testicles of the control group showed that they were round or oval in shape. As for its histological structure, it contains large numbers of coiled seminiferous tubules and is lined with germinal epithelium. Each tube contains the various stages of sperm transformation. The tubule is covered with a thin basement membrane and its wall is composed of several layers of sperm progenitor cells. The primary sperm cells are the largest cells in contact with the basal lamina and are oval in shape and also have large nuclei, while the secondary sperm cells are smaller than the primary cells and their nuclei are dark in color. As for the interstitial tissue, it is a connective tissue that connects the seminiferous tubules to each other. It contains blood vessels and cells with internal secretion called interstitial cells. Its connective tissue extends from the tubule to the periphery of the testicle, where it is linked to the tunica albuginea and surrounds the testicle.

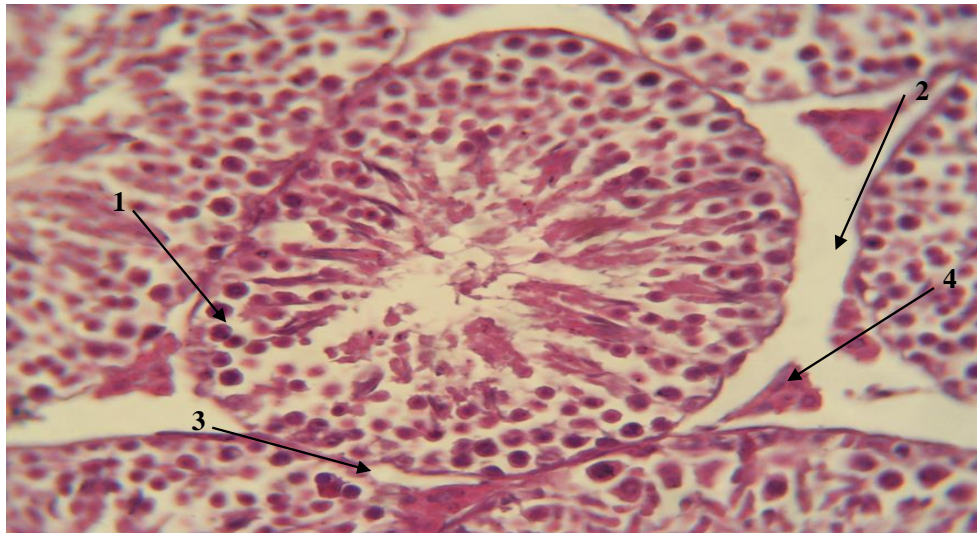


Figure (1): A cross-section of testes in male mice for the control group showing, 1 Leydig cells, 2 seminiferous tubule, 3 interstitial tissue, 4 primary sperm cells (H&E 40x).

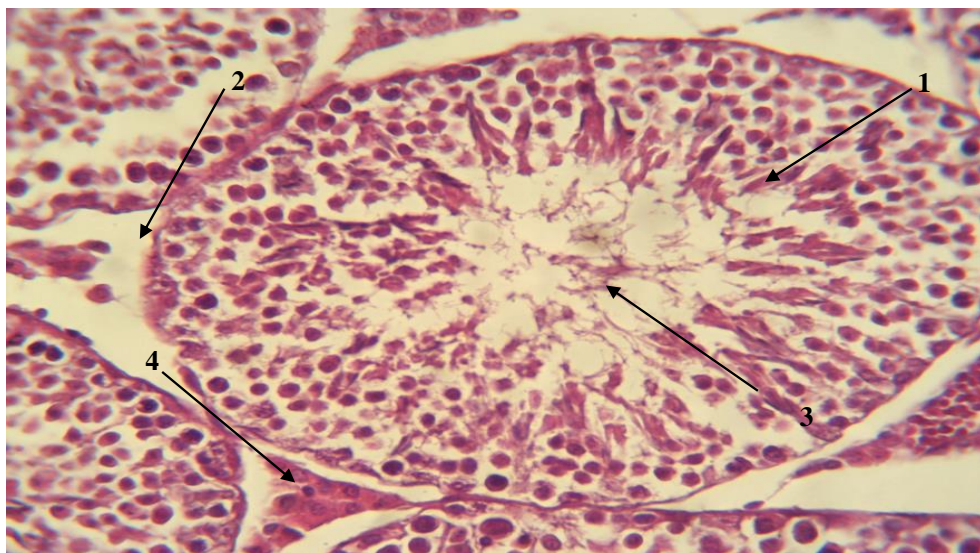


Figure (2): A cross-section of the testes of male mice for the control group showing, 1 secondary spermatocytes, 2 Sertoli cells, 3 spermatids, 4 basement membrane (H&E 40x).

In addition, findings of study showed the lack of spermatozoa in a few cavities of the seminal tubules as well as the appearance of vacuolation. In some areas of the testicle, it is clearly shown that the distance between germ cells is widened, their dissection from the tissue of epithelium and their collection in a gap of the seminal tubules, the phenomenon of deterioration in Sertolic cells and an intensify in space among



adjacent Sertolic cells as showed in the figures (3, 4, 5) and the findings of this studying also shows appearance of huge phagocytes though cavity of seminal tubules as shown in figure (6).

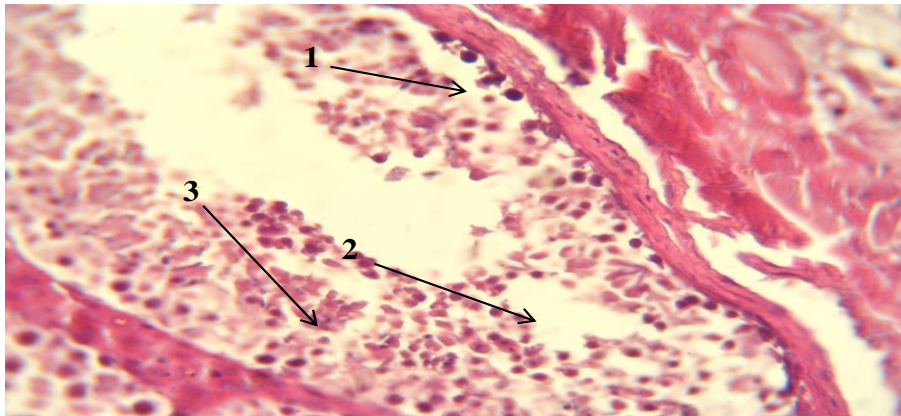


Figure (3): Cross section passing through the testicle of a white mouse injected with HCG at condensation of (0.2 mg/kg), note (1) seminal epithelial irregularity, (2) degeneration, (3) necrosis of the seminal tubules, (H&E 40x).

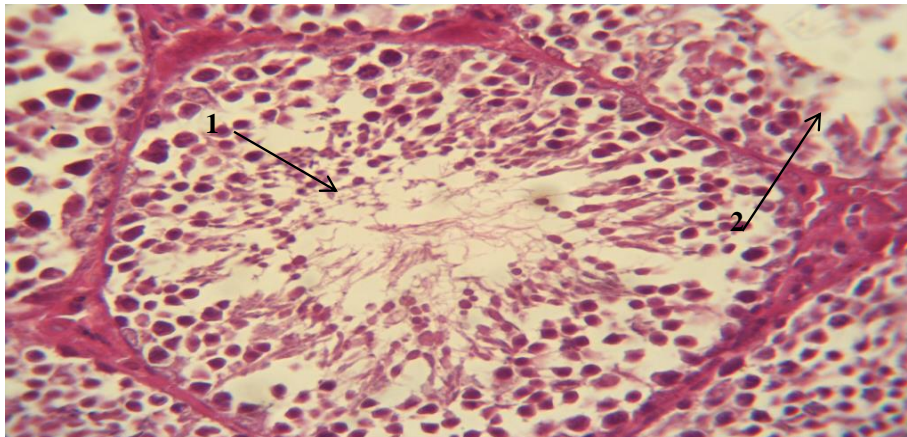


Figure (4): Cross section passing through the testicle of a white mouse injected with HCG at condensation of (0.2 mg/kg), note (1) germ cell dissection and collection in the lumen of the tubs, (2) necrosis of seminal tubules, (H&E 40x).

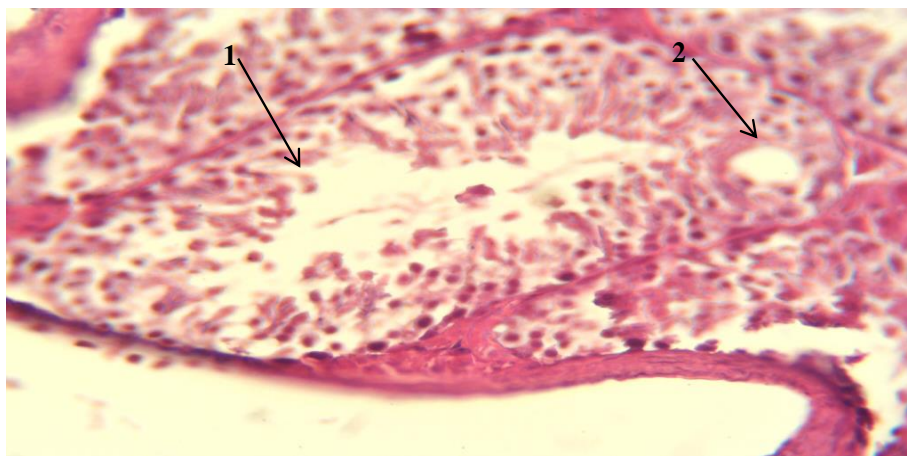


Figure (5): Cross section passing through the testicle of a white mouse injected with HCG at condensation of (0.2 mg/kg), note (1) dissected areas of tissue Epithelial of seminal tubuls, (2) degeneration or degeneration of Sertolic cells, (H&E 40x).

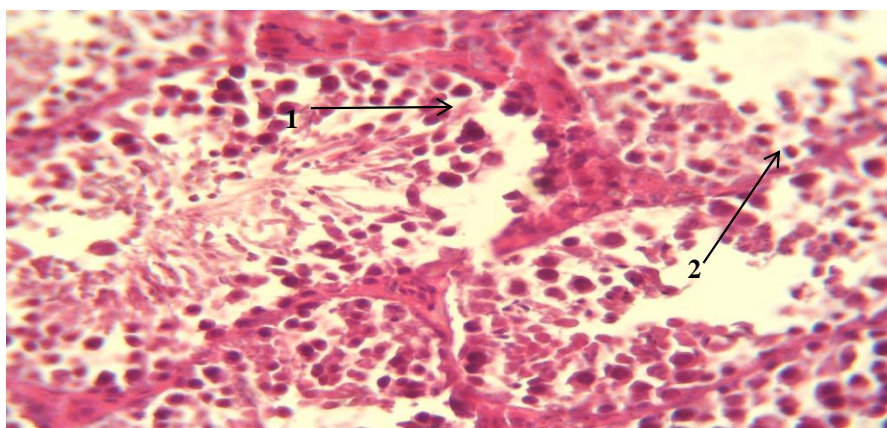


Figure (6): Cross section passing through the testicle of a white mouse injected with HCG at a concentration of 0.2 mg/kg, observed (1) appearance of huge phagocytic inside cavity of seminal tubuls, and (2) degeneration or degeneration of Sertolic cells, (H&E 40x).

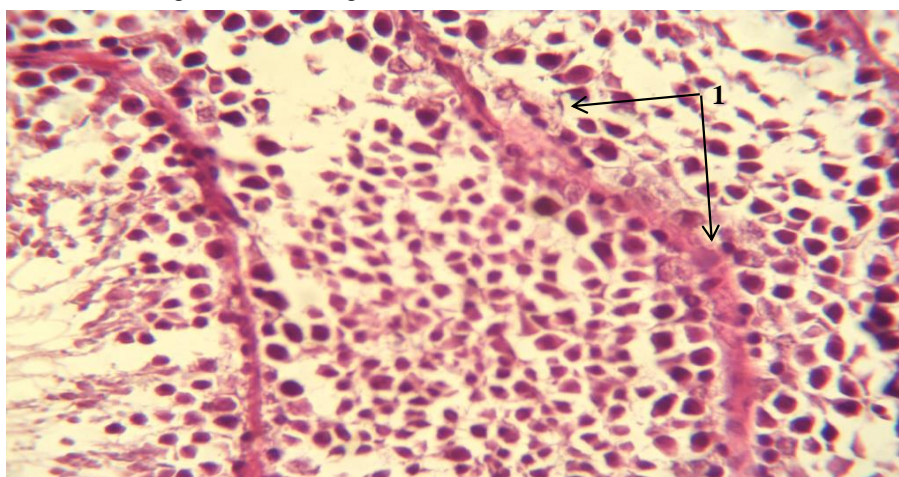


Figure (7): Cross section passing through the testicle of the white mouse injected with HCG at condensation of (0.2 mg/kg), note (1) depletion or depletion in some layers of germ cells of the seminal tubules, (H&E 40x).

[26] pointed out that a disorder in Sertolic cells would naturally impact “germ cells” and ultimately result to testicular tissue deficiency. Whereas [27] it was stated that Sertolic cell has a necessary roles in development of “germ cells” by formation a blood-testicular barrier that protects germ cells, and transporting nutrients and hormones to germ cells. It is believed that all these pathological signs are due to a defect in the structure and function of Sertolic cells. The results of the current study revealed that the drug HCG has an effect on Leydig cells and interstitial tissue, which was evident through the appearance of lysis and necrosis and also the appearance of defloration in the interstitial tissue, as shown in Figure 2. The findings of current studies are consistent with results [28] which Leydig cells are a central for regulating fruitfulness within manufacturing of Testosterone Hormone. While stated [29] “Leydig cells” are induced by Luteinizing Hormone LH, which stimulates Arachidonic acid and testosterone. The results of current studying showed that the injecting mice at a concentration of (0.2 mg of HCG / kg) lead to increased contraction of seminal tubules and depletion of depletion in some germinal layers of the seminal tubules and at the same time led to degeneration and spermatosis, apoptosis in spermatogonia, primary sperm cells, sperm blast, mature sperm and return of spermboloblasty and mature sperm into the seminiferous tubules. On the other hand, the results showed that many of the seminal tubules were emptied of germ cells as shown in the figure (5). It is thought that this might be due to a flaw in Sertolic cells, which therefore will have an impact on vital protins needed for manufacturing process required for germ differentiation of cells, as these proteins are eliminated at theirs maximum rate within spermboloblasty differentiation stage. This result is in line with its findings [30]. Through their study of sperm characteristics and exact arrangement of the testicles in animals follows extended Methanol treatment and then with what was mentioned in [31] the movement that goes back in time of the spermboloblaste and matures sperms through sperm wall tubules might be due to their alertness to the testicle being affected by Pregnyl.

## 5. Conclusion

We conclude from this study that exposure to Pregnyl led to a change in the weight rate of mice as well as behavioral and visual changes in the animals. The drug has clear effects that appeared in the testicular tissue of adult mice.



### REFERENCES:

- [1] G. A. Woldemariam and A. W. Butch, "Immunoextraction–tandem mass spectrometry method for measuring intact human chorionic gonadotropin, free  $\beta$ -subunit, and  $\beta$ -subunit core fragment in urine," *Clin Chem*, vol. 60, no. 8, pp. 1089–1097, 2014.
- [2] B. Lunenfeld, "Historical perspectives in gonadotrophin therapy," *Hum Reprod Update*, vol. 10, no. 6, pp. 453–467, 2004.
- [3] M. M. Elliott, A. Kardana, J. W. Lustbader, and L. A. Cole, "Carbohydrate and peptide structure of the  $\alpha$  and  $\beta$ -subunits of human chorionic gonadotropin from normal and aberrant pregnancy and choriocarcinoma," *Endocrine*, vol. 7, pp. 15–32, 1997.
- [4] L. A. Cole, "Hyperglycosylated hcg," *Placenta*, vol. 28, no. 10, pp. 977–986, 2007.
- [5] G. Kovalevskaya et al., "Differential expression of human chorionic gonadotropin (hCG) glycosylation isoforms in failing and continuing pregnancies: preliminary characterization of the hyperglycosylated hCG epitope," *Journal of endocrinology*, vol. 172, no. 3, pp. 497–506, 2002.
- [6] C. Nwabuobi, S. Arlier, F. Schatz, O. Guzeloglu-Kayisli, C. J. Lockwood, and U. A. Kayisli, "hCG: biological functions and clinical applications," *Int J Mol Sci*, vol. 18, no. 10, p. 2037, 2017.
- [7] W. E. Merz, "The primate placenta and human chorionic gonadotropin," *Experimental and Clinical Endocrinology & Diabetes*, vol. 102, no. 03, pp. 222–234, 1994.
- [8] H. Koistinen, L. Hautala, K. Koli, and U.-H. Stenman, "Absence of TGF- $\beta$  receptor activation by highly purified hCG preparations," *Molecular Endocrinology*, vol. 29, no. 12, pp. 1787–1791, 2015.
- [9] B. Burczynska, M. J. Booth, R. K. Iles, A. Shah, A. Shiled, and S. A. Butler, "Stable knockdown of hCG $\beta$  mRNA expression in bladder cancer cells results in significant growth inhibition," *Anticancer Res*, vol. 33, no. 9, pp. 3611–3614, 2013.
- [10] L. Ibeto et al., "Insights into the hyperglycosylation of human chorionic gonadotropin revealed by glycomics analysis," *PLoS One*, vol. 15, no. 2, p. e0228507, 2020.
- [11] S. C. Esteves, "Efficacy, efficiency and effectiveness of gonadotropin therapy for infertility treatment," *MedicalExpress*, vol. 2, p. M150302, 2015.
- [12] C. Cahoreau, D. Klett, and Y. Combarous, "Structure–function relationships of glycoprotein hormones and their subunits' ancestors," *Front Endocrinol (Lausanne)*, vol. 6, p. 26, 2015.
- [13] S. E. Bulun, "Physiology and pathology of the female reproductive axis," *Williams textbook of endocrinology*, pp. 589–663, 2016.
- [14] P. Berger and A. J. Laphorn, "Standardization of epitopes for human chorionic gonadotropin (hCG) immunoassays," *Curr Med Chem*, vol. 23, no. 30, pp. 3481–3494, 2016.
- [15] P. Berger et al., "Candidate epitopes for measurement of hCG and related molecules: the second ISOBM TD-7 workshop," *Tumor Biology*, vol. 34, pp. 4033–4057, 2013.
- [16] U.-H. Stenman and H. Alftan, "Determination of human chorionic gonadotropin," *Best Pract Res Clin Endocrinol Metab*, vol. 27, no. 6, pp. 783–793, 2013.
- [17] J. Smits and P. Platteau, "Influence of human chorionic gonadotrophin during ovarian stimulation: an overview," *Reproductive biology and endocrinology*, vol. 18, no. 1, pp. 1–17, 2020.
- [18] C. Kaulbars and G. Vaillancourt, "How Herbicide Work, Biology to Application," *Alberta Agricultural and Rural Development, Canada*, 2014.
- [19] J. D. Bancroft and M. Gamble, "Theory and practice of histology techniques," *Churchill Livingstone Elsevier, London*, pp. 83–134, 2008.
- [20] Noor Ali Hussein Alwan, Iqbal S. Mohammed, Spectrophotometric Determination of Sulfamethazole Drug by Using Azo Coupling Reaction , *Iraqi Journal for Applied Sciences: Vol. 1 No. 1 (2024)*
- [21] C. L. Yano and H. Dolder, "Rat testicular structure and ultrastructure after paracetamol treatment," *Contraception*, vol. 66, no. 6, pp. 463–467, 2002.
- [22] S. Carreau, S. Bourguiba, S. Lambard, I. Galeraud-Denis, C. Genissel, and J. Levallet, "Reproductive system: aromatase and estrogens," *Mol Cell Endocrinol*, vol. 193, no. 1–2, pp. 137–143, 2002.
- [23] K. S. Suvarna, C. Layton, and J. D. Bancroft, *Bancroft's theory and practice of histological techniques. Elsevier health sciences*, 2018.
- [24] L. L. RICHARDSON, H. K. KLEINMAN, and M. DYM, "Altered basement membrane synthesis in the testis after tissue injury," *J Androl*, vol. 19, no. 2, pp. 145–155, 1998.
- [25] K. H. Gulkesen, T. Erdogan, C. F. Sargin, and G. Karpuzoglu, "Expression of extracellular matrix proteins and vimentin in testes of azoospermic man: an immunohistochemical and morphometric study,"



- Asian J Androl, vol. 4, no. 1, pp. 55–60, 2002.
- [26] Q. Dong and M. P. Hardy, “Leydig cell function in man,” in *Male Hypogonadism: Basic, Clinical, and Therapeutic Principles*, Springer, 2004, pp. 23–43.
- [27] T. K. Monsees, M. Franz, S. Gebhardt, U. Winterstein, W. Schill, and J. Hayatpour, “Sertoli cells as a target for reproductive hazards,” *Andrologia*, vol. 32, no. 4-5, pp. 239–246, 2000.
- [28] M. M. S. Reis, A. C. Moreira, M. Sousa, P. P. Mathur, P. F. Oliveira, and M. G. Alves, “Sertoli cell as a model in male reproductive toxicology: Advantages and disadvantages,” *Journal of Applied Toxicology*, vol. 35, no. 8, pp. 870–883, 2015.
- [29] G. Kaur, L. A. Thompson, and J. M. Dufour, “Sertoli cells—immunological sentinels of spermatogenesis,” in *Seminars in cell & developmental biology*, Elsevier, 2014, pp. 36–44.
- [30] M. D. Papaioannou et al., “Sertoli cell Dicer is essential for spermatogenesis in mice,” *Dev Biol*, vol. 326, no. 1, pp. 250–259, 2009.
- [31] B. Manivannan, R. Mittal, S. Goyal, A. S. Ansari, and N. K. Lohiya, “Sperm characteristics and ultrastructure of testes of rats after long-term treatment with the methanol subfraction of *Carica papaya* seeds,” *Asian J Androl*, vol. 11, no. 5, p. 583, 2009.

### BIOGRAPHIES OF AUTHORS

	<p><b>Salam Maseer Juma'a</b> is a MSc. Student in Department of Biology – College of Education for Pure Science – University of Diyala. he can be contacted at email: <a href="mailto:salammsser92@gmail.com">salammsser92@gmail.com</a></p>
	<p><b>Dr. Thekra Atta Ibrahim</b> is Professor at College of Education for Pure Science, University of Diyala, Iraq. She received the B.Sc. degree and M.Sc. degree in biology science from the University of Diyala, IRAQ. She Holds a PhD degree in biology Science with specialization in Histological Analysis Tissue Preparation Paraffin Embedding Anatomic Pathology Immunohistology Immunocytochemistry Tissue Fixation Tissue Dissection Cryostat Sectioning and Ultrastructure. Her research areas are embryology and histology. She has published several scientific papers in national, international conferences and journals. She can be contacted at email: <a href="mailto:thekraatta@uodiyala.edu.iq">thekraatta@uodiyala.edu.iq</a>.</p>