Iraqi Journal for Applied Science (IJAS)
Vol. 2, No. 1, March, 2025, pp. 6-11
ISSN: 3006-5828, DOI: 10.69923/er966f98 ❒ 6

Phenotypic and Anatomical Structure of Thyroid Gland in Domestic Cat and Owls: A Comparative Study

Amjad Adham Ahmed[1], Ammar Ismail Jabbar[2]

[1]Department of Biology, College of Education for Pure Science,
Diyala University, Diyala, Iraq.
[2]Department of Veterinary Medicine, College of Dentistry,
Al-Iraqia University, Baghdad, Iraq.

Article Information

Article history:

Received: 06, 06, 2024
Revised: 21, 12, 2024
Accepted: 16, 01, 2025
Published: 30,03, 2025

Keywords:

thyroid gland
blood supply
cat
owl

Abstract

The purpose of the study was to compare the anatomical characteristics of the thyroid gland in two different vertebrate species: the owl (*Strix varia*) and the domestic cat (*Felis catus*). Six disease-free animals varying-aged from each species were included in the study.

The thyroid gland of the cat was found to have a right and left lobe, situated in the cervical area, entirely beneath the larynx, and connected to both sides of the trachea. These findings were obtained from a macroscopic examination of the gland. Unlike in many other mammals, the two lobes are connected by an isthmus. The thyroid lobes have a reddish-pink hue and appeared elongated

The macroscopic anatomy the owl's thyroid gland's revealed that it is symmetrically shaped, either oval or spherical, flat on the dorso-ventral side, and dark reddish-brown in color. similar to the cat, the two halves of the gland are not attached by an isthmus. The glandis located on both sides of the trachea and on the ventral side of the back of the neck.

This is an open access article under the CC BY-SA license.

Corresponding Author:

Amjad Adham Ahmed
Department of biology Science, College of Education for Pure Science
University of Diyala
Baqubah City, Diyala Governorate, Iraq
Email: ***amjad.adham@uodiyala.edu.iq***

1. INTRODUCTION

The thyroid gland is one of the most significant endocrine glands in the body, as it regulates the body's metabolic rate, central nervous system, anterior pituitary gland, general circulation, and plasma proteins [1] [2]. The thyroid gland produces and secretes hormones that impact various bodily functions. Tetraiodothyronine (T4) and triiodothyronine (T3) are the two amino hormones produced by the gland, collectively known as thyroid hormone [3]. Thyroid hormones are crucial to an individual's life, as they regulate numerous metabolic systems and play a major role in growth and development processes. By accelerating metabolism, they increase oxygen consumption and heat production in most bodily tissues, including the heart, liver, kidney, and skeletal muscle. This process involves fat metabolism, where lipids and broken down and fatty acids are generated as an energy source [4]. The thyroid gland is reddish-brown in color and shaped like a butterfly. It has two lobes, one on each side of the trachea, and is situated in the front section beneath the larynx. The gland's right and left lobes are joined by an isthmus, and each lobe is encircled by a thick layer of internal connective tissue, dividing the lobe into small lobules [5]. In birds, the thyroid gland is located on the ventral side of the back of the neck, with one lobe on each side of the trachea. Its shape is oval or flat, and its color varies from red to reddish brown to dark red [6].

The current study aimed to identify the phenotypic and anatomical description and conduct a comparative study of the thyroid gland in two species of vertebrates: the domestic cat (*Felis catus*) from mammals, and the owl (*Strix varia*) from birds.

1. METHOD

Samples Collection :

Six animals, both cat and owl, were used in this study. They were selected as active, disease-free, and of different ages. The owls were obtained from the spinning market in Baghdad, and the cat was caught with a special trap at diyala governorate.

Dissecting :

The cat and the owl were anesthetized for the purpose of euthanasia by injecting a dose of Xylazine (4.3 mg/kg) , Kitamine (29.1 mg/kg) The cat was injected into the muscle in the thigh area, and the owl was injected into the muscle in the chest area, according to what he mentioned [7] [8]. The animals were dissected by making a longitudinal incision along the abdominal midline from the neck area to the lower abdomen area, then the entrance to the chest and neck was opened, then the body cavity area was carefully opened and After the thyroid gland was removed, the ribs were sliced on both sides and elevated to reveal the heart and major arteries within the rib cage. In order to determine the gland's dimensions anatomically, including its length, width, weight, and thickness. As well as the visual description, in addition to the anatomical location and blood supply of the gland. All observations of the gland were recorded (color, size, shape), and the two animals, the cat and the owl, were injected with a substance consisting of a mixture of latex and carmine dye for the purpose of identifying. the blood supply to the thyroid gland. The substance was injected with a 10-cc syringe through a rubber tube into the left ventricle.

For each animal, after making an incision in the left ventricle and bleeding the animal, the animal was left after the injection for 6 hours, then the entire animal was placed in a fixation solution (10% formalin), and the animal was later dissected for the purpose of identifying the blood supply to the gland.

2. RESULTS AND DISCUSSION

3-1 Morphological Description Thyroid gland in the Cat

Ording to the results of the macroscopic autopsy the thyroid gland in the cat is made up of two lobes, located in the cervical region just below the larynx, and is Connecticut to both sides of the trachea, The thyroid lobe appears elongated and reddish-pink, see figure 1.

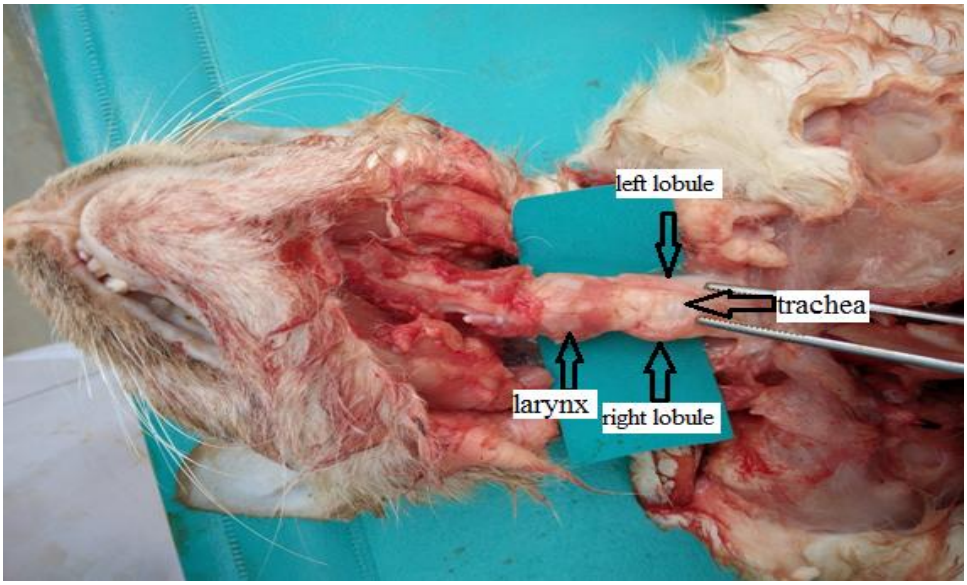

Figure 1: Anatomical section of cat thyroid gland demonstrating the gland's location and structure.

This result is consistent with the results of several researchers who studied the thyroid gland, and perhaps these results are consistent with the fact that all vertebrates have the same body plan, and this is consistent with the results of a study conducted by [9]. that the thyroid gland in the adult hedgehog It is located in the neck area on both sides of the trachea) and the gland consists of two lobes, right and left.

Additionally, it is consistent with findings from a study on the thyroid gland in weasels by [10], which demonstrated that the gland in an adult animal is situated in the cervical region beneath the larynx and is connected to the trachea. The results of the current study indicate the absence of an isthmus that connects the two lobes, this is in line with the findings of a study conducted in [9], which demonstrated that the hedgehog's thyroid glands two lobes did not form isthmus. However, other research on a variety of vertebrates, such as that on the thyroid gland in donkeys [11]. and rats [12]. has shown the existence of an isthmus connecting the thyroid glands two lobes, and this is not consistent with the study present.

The results of the study showed that the right lobe was heavier, longer, and thicker than the left lobe. The average weight of the right lobe was 0.114 grams, the average length was 18.66 mm, and the average thickness was 2.24 mm. Likewise, the average weight of the left lobe was 0.105 grams, the average length was 15.67 mm, and the average thickness was 2.12 mm, while the average width of the left lobe was larger than the right lobe, reaching 6.75 mm. 5.45 mm respectively.

3-2 Blood supply Thyroid gland in the Cat

Macroscopic autopsy results showed that the main blood supply to the thyroid gland in the cat is from the cranial thyroid artery, which is a branch of the common carotid artery see figure 2. This result is consistent with what was stated by [13] that in most vertebrates, the arterial blood supply to the thyroid gland is via the thyroid arteries, which are the cranial thyroid artery and the caudal thyroid artery, which branch off from the common carotid artery.

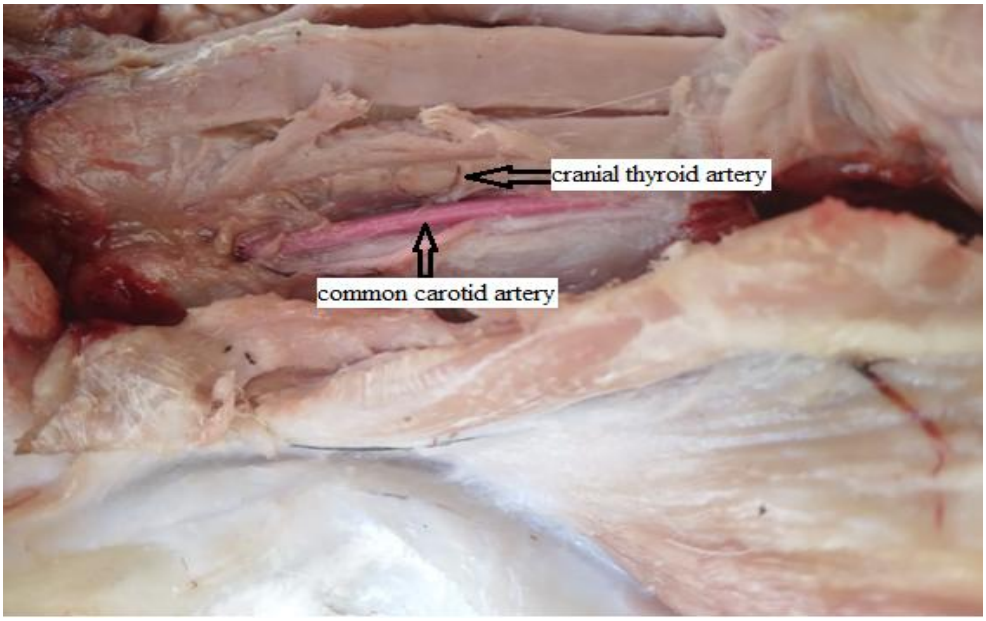

Figure 2: The cat's thyroid gland's blood supply

3-3 Morphological Description Thyroid gland in the Owl

Macroscopic anatomy results revealed that owls have symmetrical, oval or spherical thyroid glands that are flat on the dorso-ventral side and dark reddish-brown in colour. The two glandular parts are not connected to the isthmus, this similar to what was seen in cat, see figure 3. The results indicate that the thyroid gland in owls is similar to the shape and color of the gland in other poultry birds, and this result is consistent with the results of researchers [14]. in their study of chickens. And the results of [15]. in his study on the long-legged buzzar.The thyroid gland is located on the ventral side of the back of the neck, on both sides of the trachea, close to the jugular veins and common carotid arteries at the point where the common carotid arteries split to emerge from the anterior cervical and vertebral arteries, according to the results of the morphological description, see figure 4.

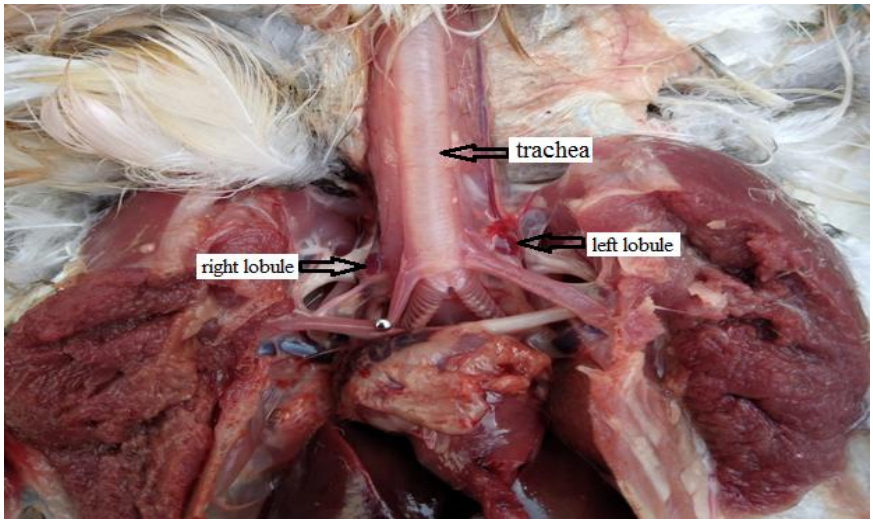

Figure 3: An anatomical section of the thyroid gland's position in an owl's

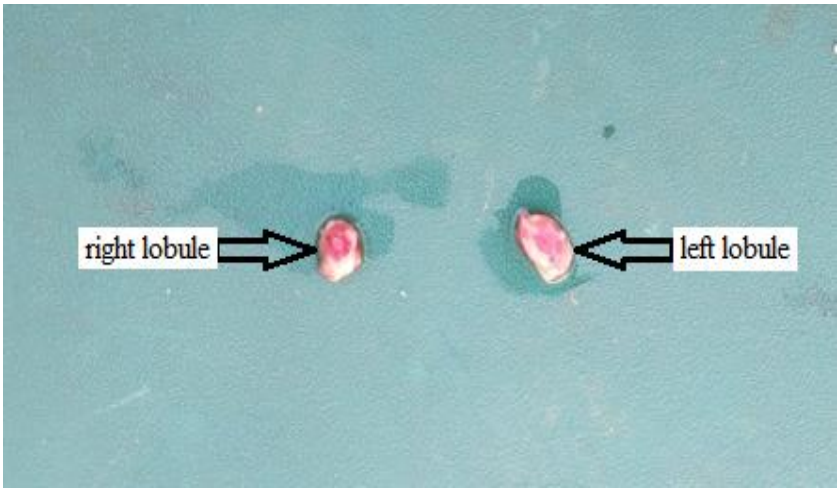

Figure 4: Anatomical section demonstrating the owl thyroid gland's oval form.

These results are similar to the results of researchers in their study of other poultry birds [16], in chickens [17] [18]. in the Kuttanad duck [19]. in pigeons and [15]. in the long-legged hawk. and [20] in turkeys . The results of the study showed that the left lobe was heavier, longer, and wider than the right lobe. The average weight of the left lobe was 0.027 grams, the average length was 4.34 mm, and the average width was 3.20 mm. Likewise, the average weight of the right lobe was 0.022 grams, the average length was 3.94 mm, and the average width was 2.85 mm, while the average thickness of the right lobe was greater than the left lobe, reaching 2.57 mm. – 1.71 mm, respectively.

3-4 Blood supply Thyroid gland in the Owl

Macroscopic autopsy results showed that the main blood supply to the thyroid gland in owls is from three arteries branching off from the common carotid artery: the thyroid cranial artery, the middle thyroid artery, and the caudal thyroid artery, see figure 5.

These findings are in line with the research conducted by [11]. in that the thyroid glands on a turkey are symmetrical and situated near the common carotid artery at the opening of the chest. The cranial or anterior thyroid artery, the middle thyroid artery, and the thyroid artery dorsal or posterior. provide blood flow to the thyroid gland.

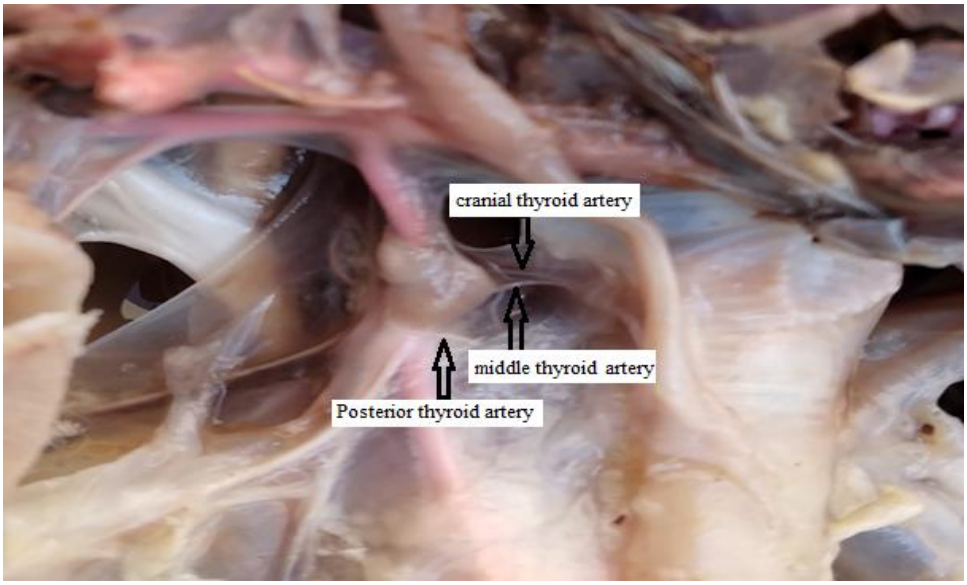

Figure 5: Owl's thyroid gland's blood supply

3. CONCLUSION

The thyroid gland in the cat consists of two lobes, right and left, and is located in the neck region just below the larynx at rings (1-6) and is attached on both sides of the trachea. The isthmus connecting the two lobes has not been observed. The thyroid gland in the owl is a pair of symmetrical oval or spherical glands, flattened on the dorsoventral side, and the two parts of the gland are not connected by the isthmus, which is similar to what has been observed in the cat.The study showed an anatomical difference in the thyroid gland between cats and owls.

REFERENCES

[1] G. Tortora and R. Sandra, Principles of Anatomy and Physiology , John Wiley and Sons, 2000.

[2] S. A. Gilkar, U. L. Shabir, and A. K. Javaid, "Association between thyroid function and body mass index in normal population," Al Amean J. Med. Sci. , vol. 4, no. 3, pp. 254–262, 2011.

[3] Vander, Human physiology. The mechanism of body Function , 8th ed., II. Biological control system, Chapter 10: Principal of hormonal control systems, McGraw–Hill Companies, 2001, pp. 263–299.

[4] G. A. Brent, "Mechanisms of thyroid hormone action," J Clin Invest , vol. 122, pp. 3035–3043, 2012.

[5] V. P. Eroschenko, Atlas of histology with functional correlations , 11th ed., Lippincott Williams and Wilkins, London, 2005.

[6] P. Yonkova, Comparative morphological studies of the thyroid gland, parathyroid glands and thymus in broiler chickens, turkeys and ducks , Monografiya, Izdatelstvo „Kota“, Stara Zagora, ISBN – 978-954-305-602-6, 2021.

[7] V. S. Harikrishnan, "Anaesthesia, Analgesia and Euthanasia of Laboratory Rodents and Rabbits: A Practical Approach," in Essentials of Laboratory Animal Science: Principles and Practices , pp. 541–562, 2021.

[8] P. Hedenqvist and L. J. Hellebrekers, "Laboratory animal analgesia, anesthesia, and euthanasia," in Handbook of laboratory animal science , vol. 1, pp. 413–45, 2003.

[9] R. A. AL-Aamery and H. A. Dauod, "Anatomical and histological study of thyroid gland in hedgehog (Hemiechinus auritus)," Journal of Madenat Alelem University College , vol. 8, no. 1, pp. 133–145, 2016.

[10] R. A. Al-Aamery and H. A. Dauod, "Anatomical and Histological Study of Thyroid Gland in Weasel (Herpestes javanicus)(E. Geoffroy saint. Hilaire, 1818)," Ibn AL-Haitham Journal For Pure and Applied Science , vol. 29, no. 1, 2017.

[11] S. A. Ali, "Anatomical and histological study of thyroid gland in female local donkeys (Eqws africanus ansinus) at Basrah city," AL-Oadisiya J. Vet. Med. Sci. , vol. 13, no. 1, pp. 85–87, 2014.

[12] C. O. Igbokwe, "Gross and microscopic anatomy of thyroid gland of the wild African grasscutter (Thryonomys swinderianus, Temminck) in Southeast Nigeria," Eur. J. Anat. , vol. 14, no. 1, pp. 5–10, 2010.

[13] F. S. Greenspan and D. G. Gardner, Basic and Clinical Endocrinology , Lang Medical Books/MC Graw-Hill, Medical Publishing Division, New York, St. Louis, San Francisco, pp. 624–629, 2001.

[14] M. Ritchie and A. A. Pilny, "The Anatomy and Physiology of the Avian Endocrine System," Vet. Clin. Exot. Anim. , vol. 11, pp. 1–14, 2008.

[15] B. Onuk and M. Kabak, "Localization of the ultimobranchial gland, thyroid gland and parathyroid gland in long-legged buzzard (Buteorufinus)," Ankara Univ Vet Fak Derg , vol. 59, pp. 81–84, 2012.

[16] B. Doneley, Avian Medicine and Surgery in Practice: Companion and Aviary Birds , Manson Publishing Ltd., 73 Corringham Road, London, pp. 30–33, 2010.

[17] F. Dar and K. Lucy, "Epithelial Diversification of Thyroid Gland in Kuttanad Duck (Anas platyrhynchos domesticus) - A Postnatal Study," British Journal of Poultry Sciences , vol. 2, no. 1, pp. 07–10, 2013.

[18] F. A. Dar, K. M. Lucy, and J. J. Chungath, "Comparison of Thyroid Gland Parameters With Body Weight and Age in Kuttanad Ducks During Postnatal Period," J. Vet. Anim. Sci. , vol. 43, pp. 71–74, 2012.

[19] S. Bose and V. K. Das, "A morphological study of calcium regulating glands in Yellow footed green pigeon, Teron phoenicoptera phoenicoptera (Lathum)," GERF Bulletin of Biosciences , vol. 3, no. 1, pp. 1–6, 2012.

[20] H. K. Ali and S. M. Mirhish, "Anatomical and Histological Study of Thyroid, Parathyroid and Ultimobranchial Glands in Iraqi Local Breed Turkey “Meleagris gallopavo”," Iraqi Journal of Veterinary Medicine , vol. 39, no. 1, pp. 40–48, 2015.

BIOGRAPHIES OF AUTHORS



Amjad Adham Ahmed: Lecturer at the College of Education for Pure Sciences, University of Diyala, Iraq. She holds a Bachelor's degree in Life Sciences from the University of Diyala in Iraq and a Master's degree from the University of Diyala in Iraq. Her research areas are Life Sciences. She has published many scientific papers in national and international conferences and journals. She can be contacted at Email : **amjad.adham@uodiyala.edu.iq**



Dr Ammar Ismail Jabbar: Associate Professor, College of Dentistry, University of Iraq, Iraq. He received his Bachelor's degree in Veterinary Medicine from University of Baghdad and his Master's degree from University of Baghdad, Iraq. He holds a PhD in Veterinary Medicine with a specialization in Anatomy and Histology. His research areas are Anatomy and Histology. He has published many scientific papers in national and international conferences and journals. He can be contacted at Email: **ammar.i.jabbar@aliraqia.edu.iq**